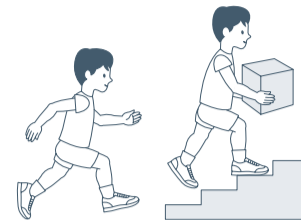


Australian Hip Surveillance Guidelines for children with Cerebral Palsy 2014

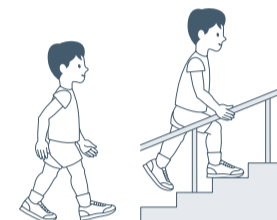
GMFCS I

- Initial clinical assessment and antero-posterior (AP) pelvic radiograph at 12-24 months of age (or at identification if older than 24 months)
- Review at 3 years of age
 - Verify GMFCS level
 - If GMFCS I is confirmed, repeat clinical assessment. AP pelvic radiograph is **NOT** required
- If GMFCS level has changed, ongoing surveillance according to confirmed classification
- If identified as Winters, Gage and Hicks (WGH) IV hemiplegia, ongoing surveillance according to WGH IV classification
- Review at 5 years of age
 - Verify GMFCS level
- If GMFCS I is confirmed, repeat clinical assessment. AP pelvic radiograph is **NOT** required and if nil other significant signs, discharge from surveillance
- If GMFCS level has changed, ongoing surveillance according to confirmed classification
- If identified as WGH IV hemiplegia, ongoing surveillance according to WGH IV classification



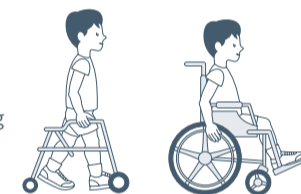
GMFCS II

- Initial clinical assessment and AP pelvic radiograph at 12-24 months of age (or at identification if older than 24 months)
- Review 12 months later
 - Verify GMFCS level
 - If GMFCS II confirmed, repeat clinical assessment and AP pelvic radiograph
 - If GMFCS level has changed, ongoing surveillance according to confirmed classification
 - If MP is abnormal and/or unstable, continue 12 monthly surveillance until stability is established
 - When MP is stable, review at 4-5 years of age
- Review at 4-5 years of age
 - Verify GMFCS level
 - If GMFCS II confirmed, repeat clinical assessment and AP pelvic radiograph
 - If GMFCS level has changed, or if identified as WGH IV hemiplegia, ongoing surveillance according to confirmed classification
 - If MP is stable, review at 8-10 years of age
 - If MP is abnormal and/or unstable, continue 12 monthly surveillance until stability is established
- Review at 8-10 years of age, prepuberty
 - Verify GMFCS level
- If GMFCS II confirmed, repeat clinical assessment and AP pelvic radiograph
- If GMFCS level has changed, or if identified as WGH IV hemiplegia, ongoing surveillance according to confirmed classification
- If MP is stable, discharge from surveillance
- If MP is abnormal and/or unstable, continue 12 monthly surveillance until stability is established or skeletal maturity
- In the presence of pelvic obliquity, leg length discrepancy or deteriorating gait, continue 12 monthly surveillance



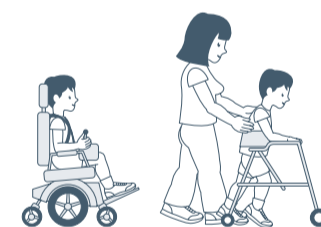
GMFCS III

- Initial clinical assessment and AP pelvic radiograph at 12-24 months of age
- Review 6 months later
 - Verify GMFCS level
 - If GMFCS III confirmed, repeat clinical assessment and AP pelvic radiograph
 - If GMFCS level has changed, ongoing surveillance according to confirmed classification
 - If MP is abnormal and/or unstable, continue 6 monthly surveillance until MP stability is established
- When MP is stable, reduce frequency to 12 monthly surveillance
- Review at 7 years of age
 - Verify GMFCS level
 - If GMFCS III confirmed, repeat clinical assessment and AP pelvic radiograph
 - If GMFCS level has changed, ongoing surveillance according to confirmed classification
 - If MP is abnormal and/or unstable, continue 6 monthly surveillance until MP stability is established
- If MP is stable, below 30%, and gross motor function is stable, AP pelvic radiographs may be discontinued until prepuberty
- 12 monthly AP pelvic radiographs must resume prepuberty and continue until skeletal maturity
- At skeletal maturity, in the presence of pelvic obliquity, leg length discrepancy or deteriorating gait, continue 12 monthly surveillance



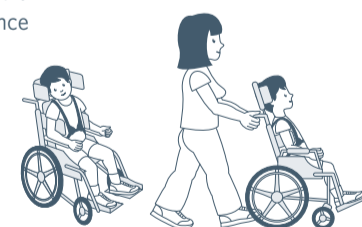
GMFCS IV

- Initial clinical assessment and AP pelvic radiograph at 12-24 months of age
- Review 6 months later
 - Verify GMFCS level
 - If GMFCS IV confirmed, repeat clinical assessment and AP pelvic radiograph
 - If GMFCS level has changed, ongoing surveillance according to confirmed classification
- If MP is abnormal and/or unstable, continue 6 monthly surveillance until MP stability is established
- When MP is stable, reduce frequency of surveillance to 12 monthly
- Review at 7 years of age
 - If MP is stable, below 30% and gross motor function is stable, surveillance may be discontinued until prepuberty
 - 12 monthly AP pelvic radiographs must resume prepuberty and continue until skeletal maturity
- Independent of MP, when clinical and/or radiographic evidence of scoliosis or pelvic obliquity is present, 6 monthly surveillance is required until skeletal maturity
- At skeletal maturity, if MP is abnormal and progressive scoliosis or significant pelvic obliquity is present continue 12 monthly surveillance



GMFCS V

- Initial clinical assessment and AP pelvic radiograph at 12-24 months of age
- Review 6 months later
- Repeat clinical assessment and AP pelvic radiograph
 - Verify GMFCS level
 - If GMFCS V confirmed, continue 6 monthly surveillance until 7 years of age or until MP stability is established
- If GMFCS level has changed, ongoing surveillance according to confirmed classification
- Review at 7 years of age
 - If MP is stable, below 30% and gross motor function is stable, continue 12 monthly surveillance until skeletal maturity
- Independent of MP, when clinical and/or radiographic evidence of scoliosis or pelvic obliquity is present, 6 monthly surveillance is required until skeletal maturity
- At skeletal maturity, if MP is abnormal and progressive scoliosis or significant pelvic obliquity is present, continue 12 monthly surveillance

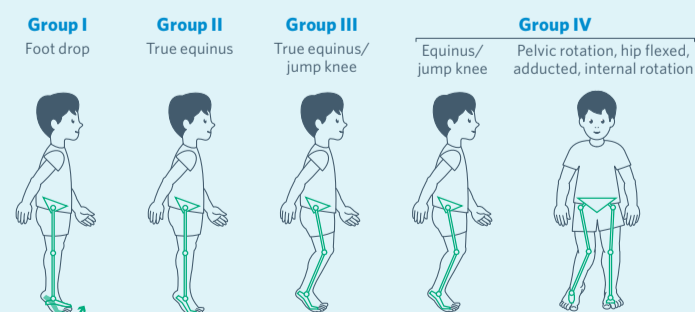


Winters, Gage and Hicks hemiplegia group IV (WGH IV)

WGH IV gait pattern clearly declares itself by 4-5 years of age. The child with a classification of WGH IV has the potential for late onset progressive hip displacement regardless of GMFCS level.

- Review at 5 years of age
 - Verify WGH and GMFCS
 - If WGH I-III, ongoing hip surveillance according to confirmed GMFCS
 - If WGH IV and MP stable, review 10 years of age
 - If MP is abnormal and/or unstable, continue 12 monthly surveillance until MP stability established

- Review at 10 years of age
 - Verify WGH IV
 - If WGH IV confirmed, repeat clinical assessment and AP pelvic radiograph
 - Continue 12 monthly surveillance until skeletal maturity
- At skeletal maturity if significant scoliosis, pelvic obliquity, leg length discrepancy or deteriorating gait, continue 12 monthly surveillance



Gait patterns in hemiplegia (Winters, Gage and Hicks, 1987)